

# Ankle Distraction: patient education

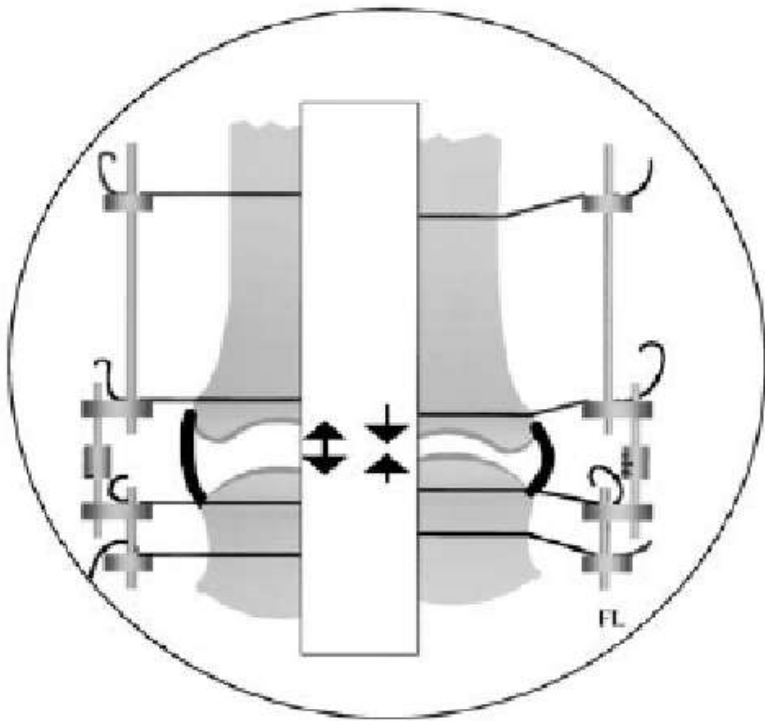
S. Robert Rozbruch, MD

LIMB .COM

HOSPITAL  
FOR  
SPECIAL  
SURGERY



# Ankle Distraction



Mechanical unloading  
of the joint

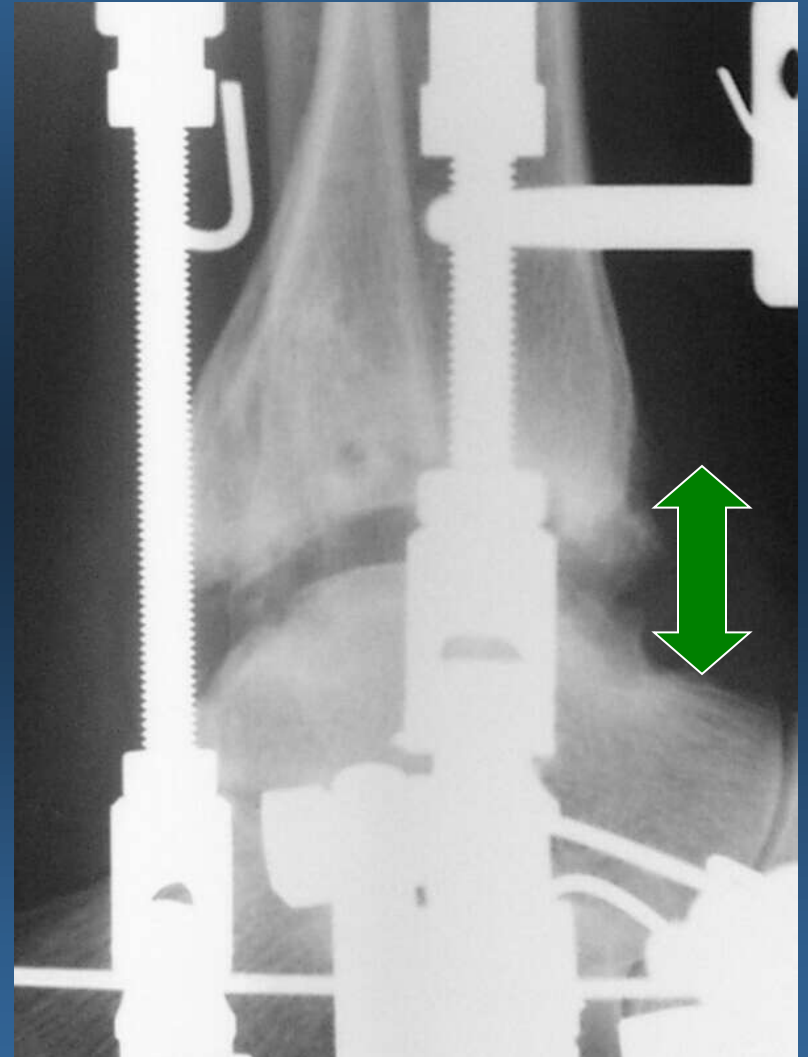
- Cartilage reparative process

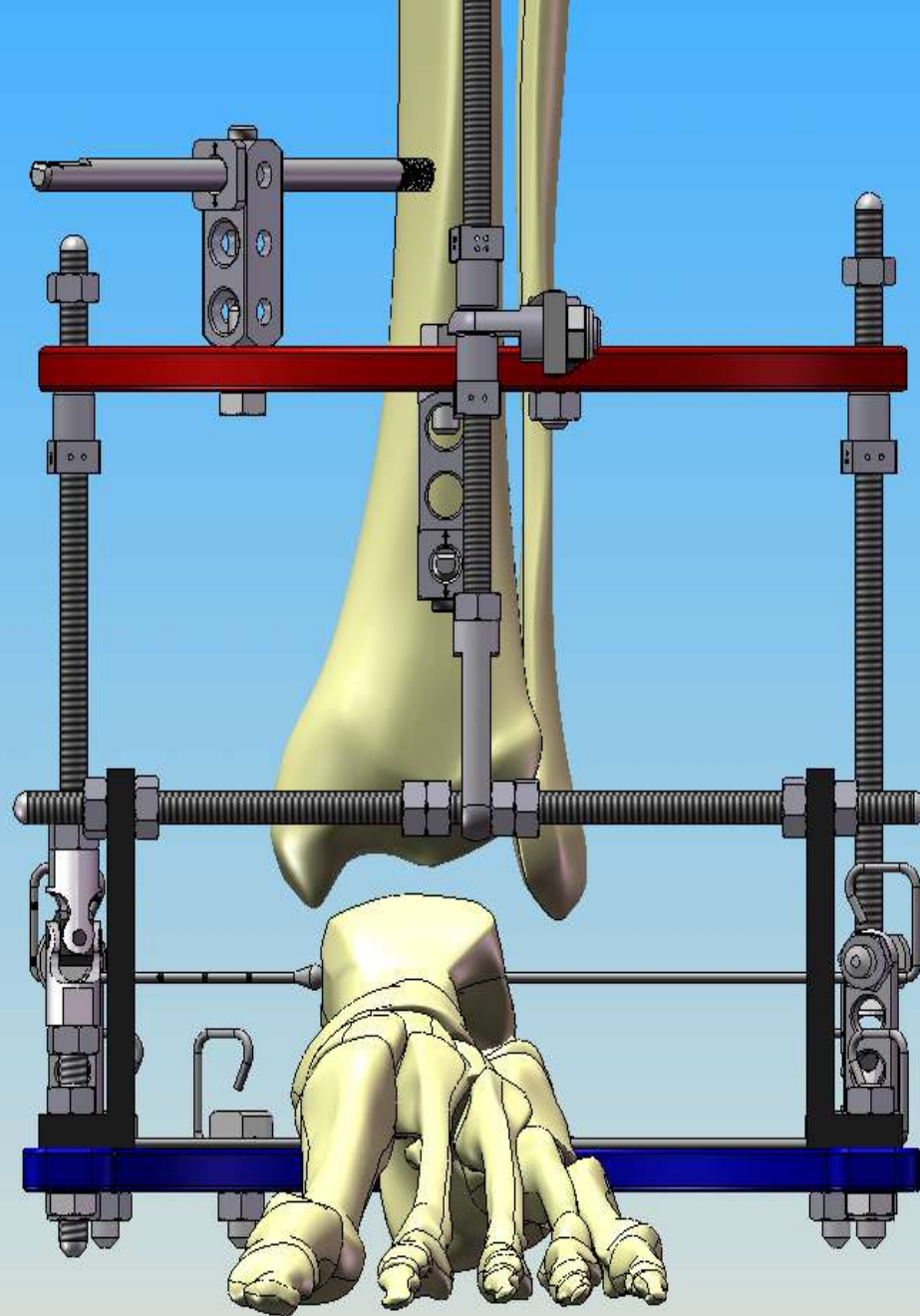
Intermittent flow of  
joint fluid and changes  
in hydrostatic pressure

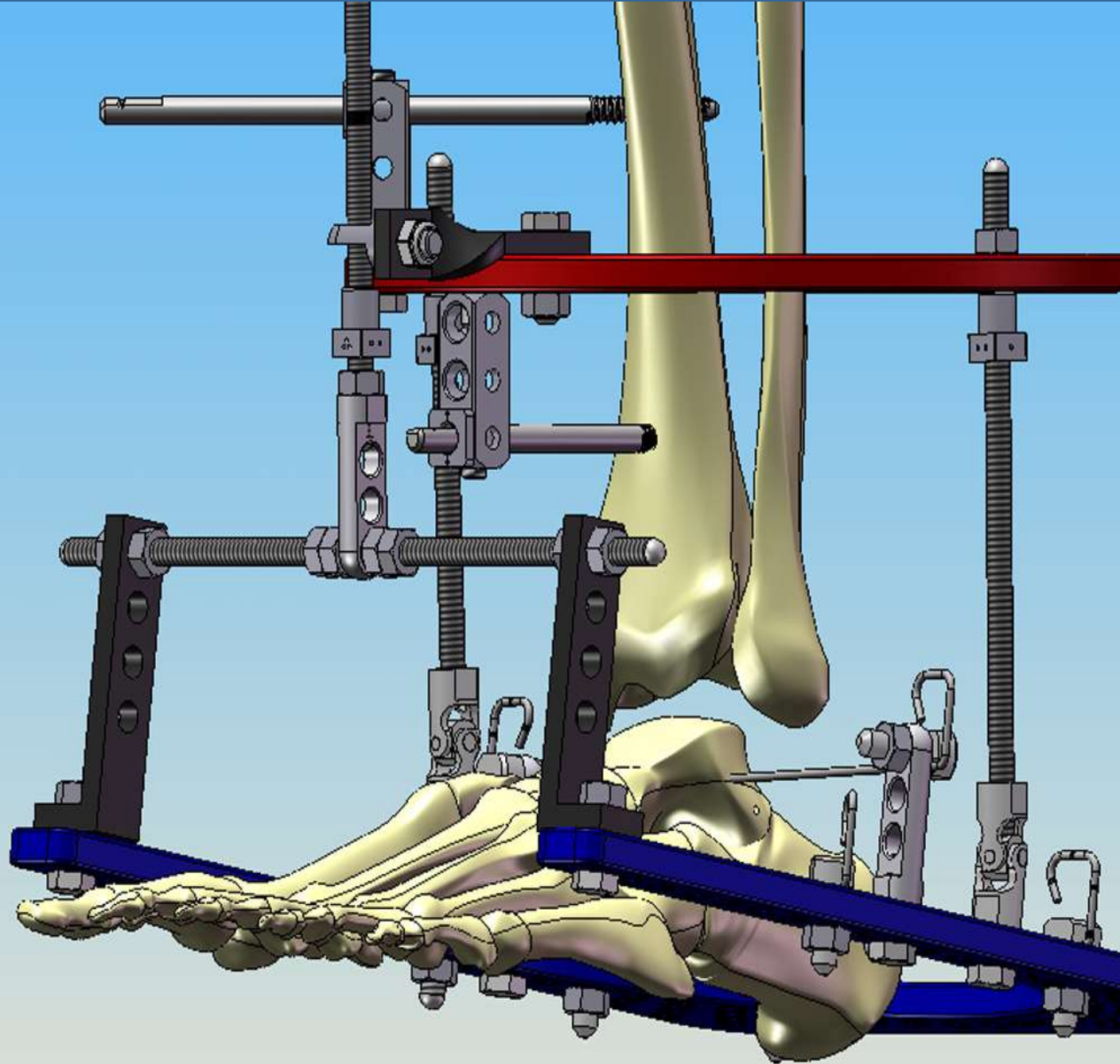
- Weight bearing and ankle  
movement in frame

# Mechanism

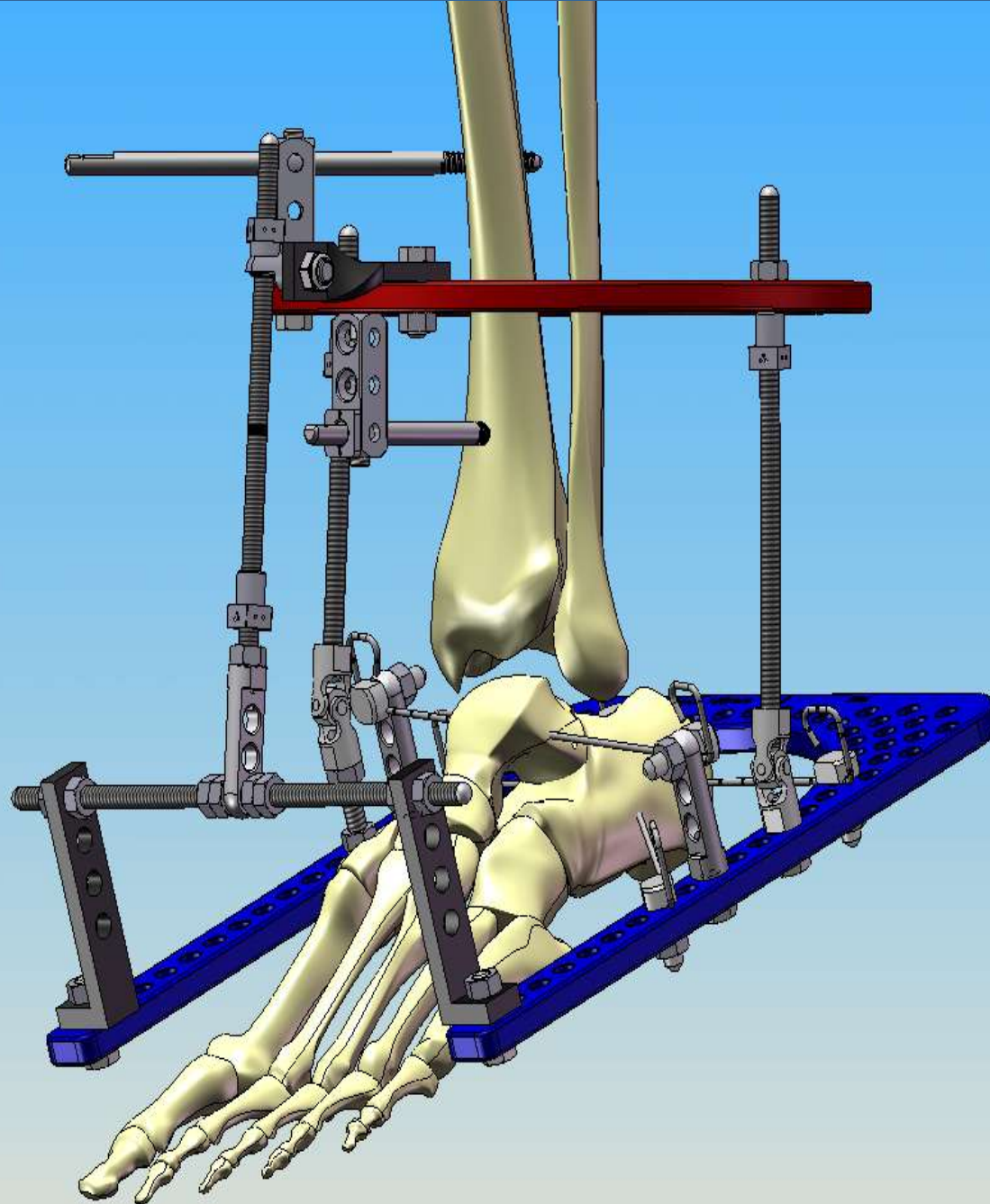
- Ilizarov external fixation for Distraction
- Combined w/ resection of anterior osteophyte & chondral stimulation

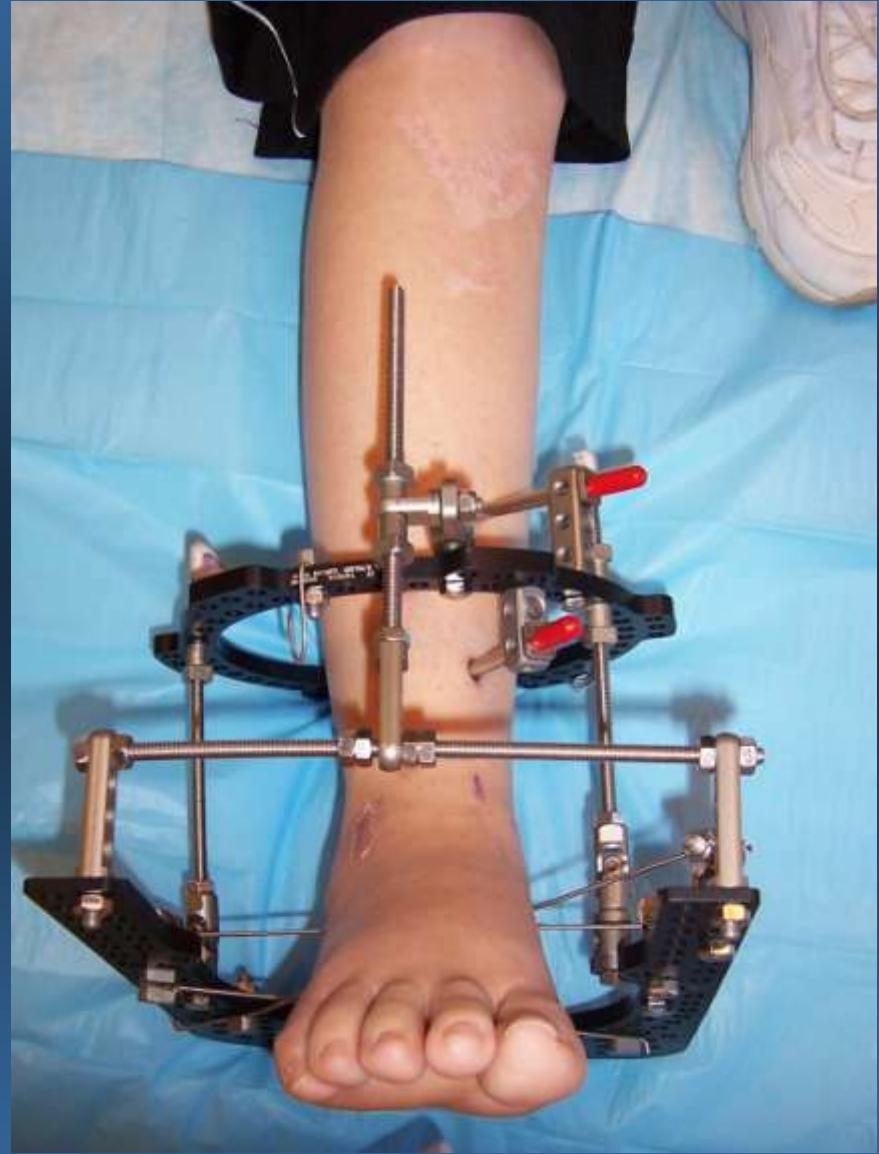






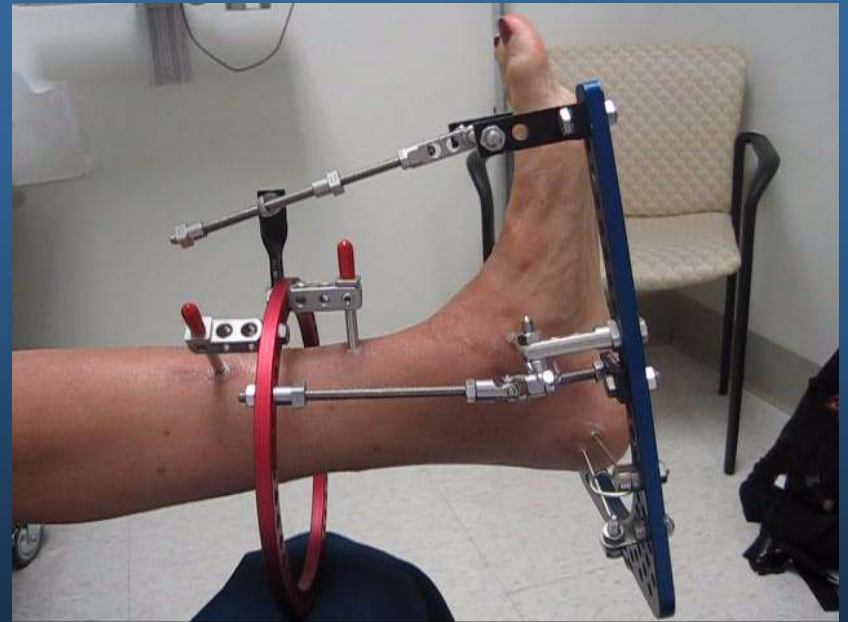
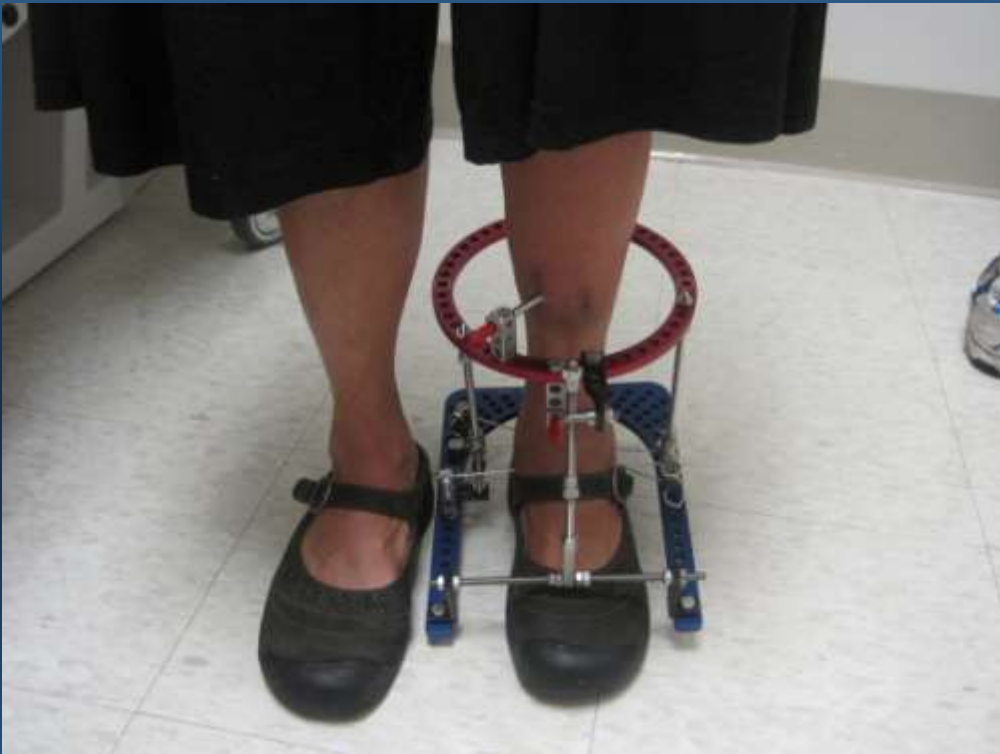




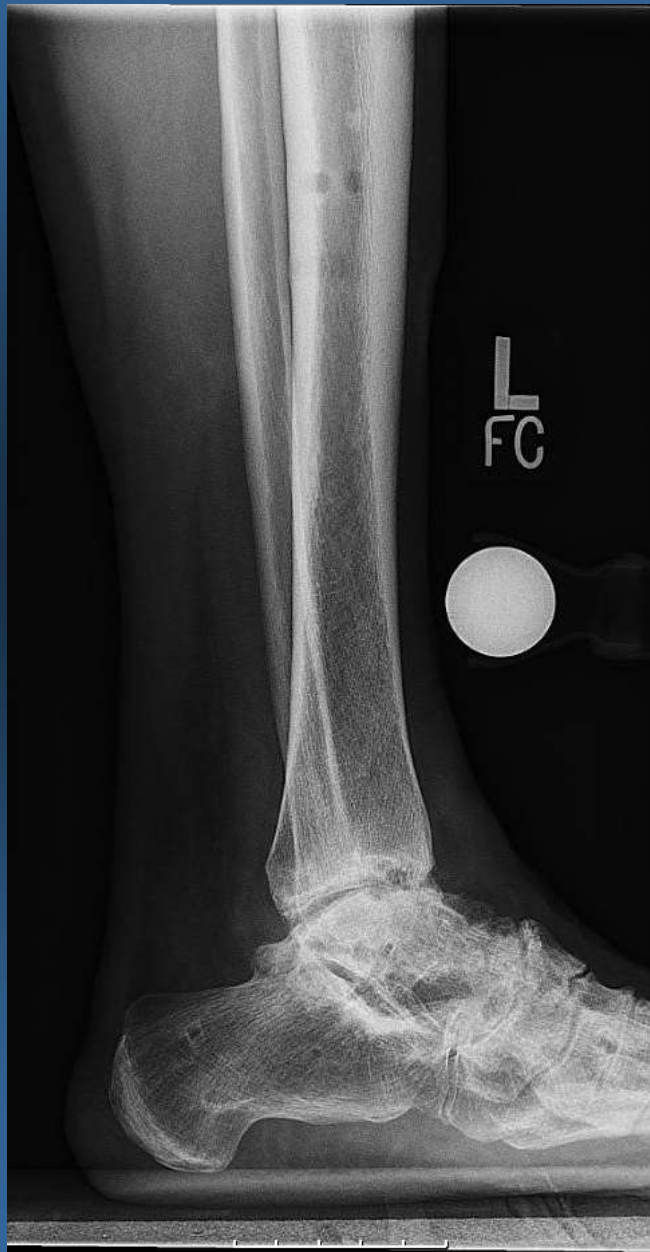




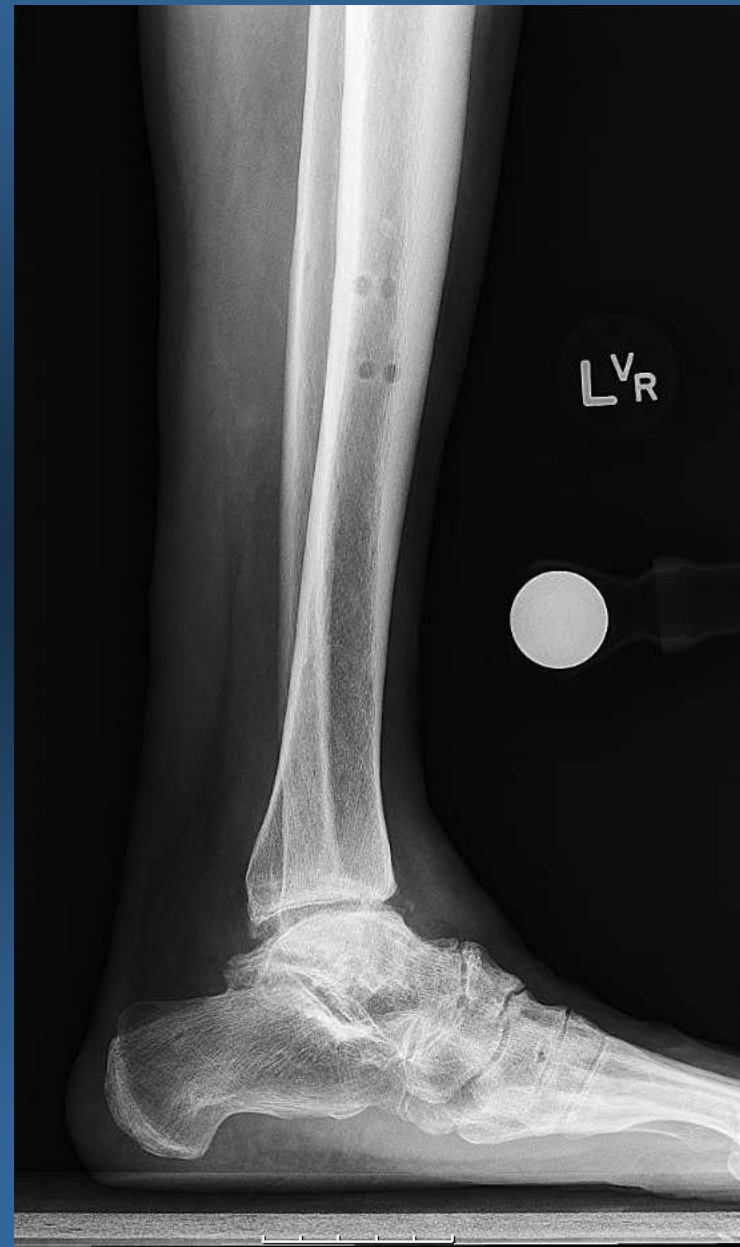


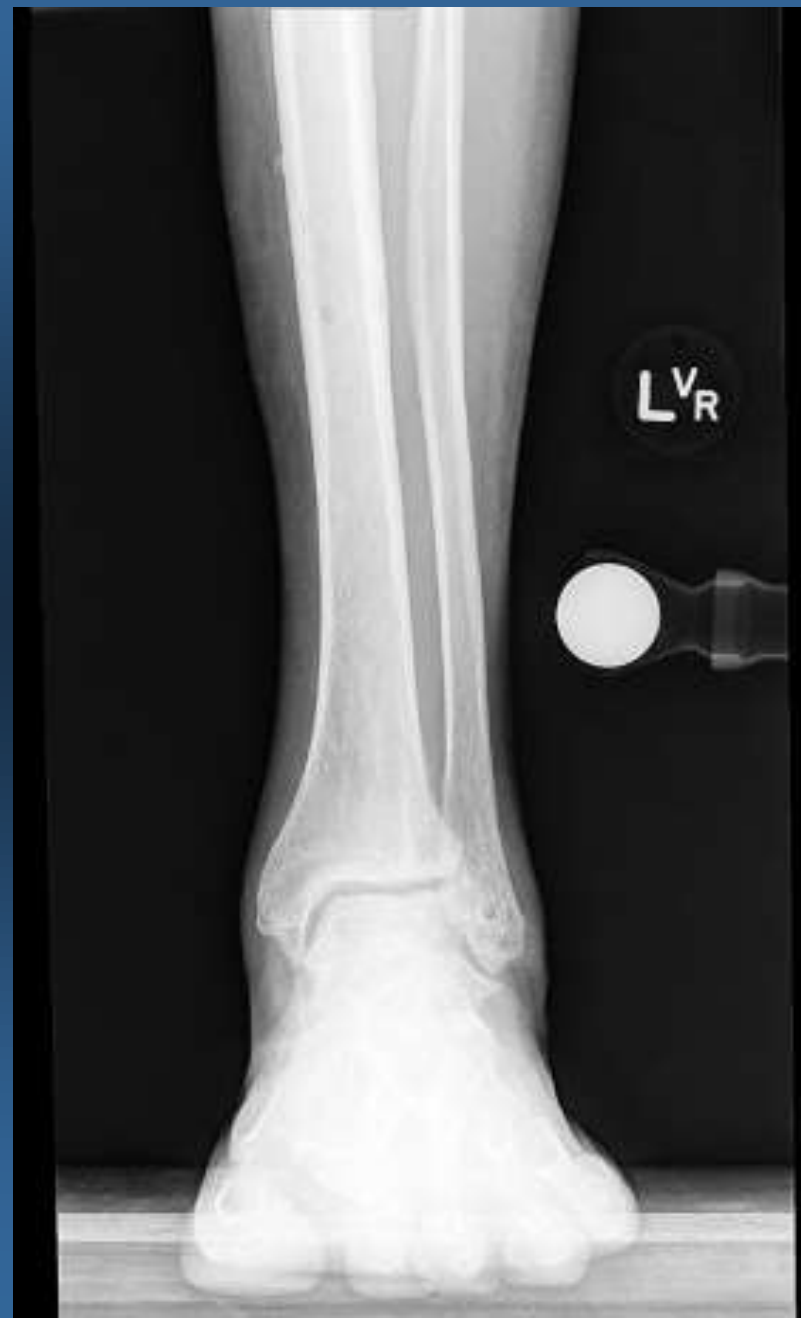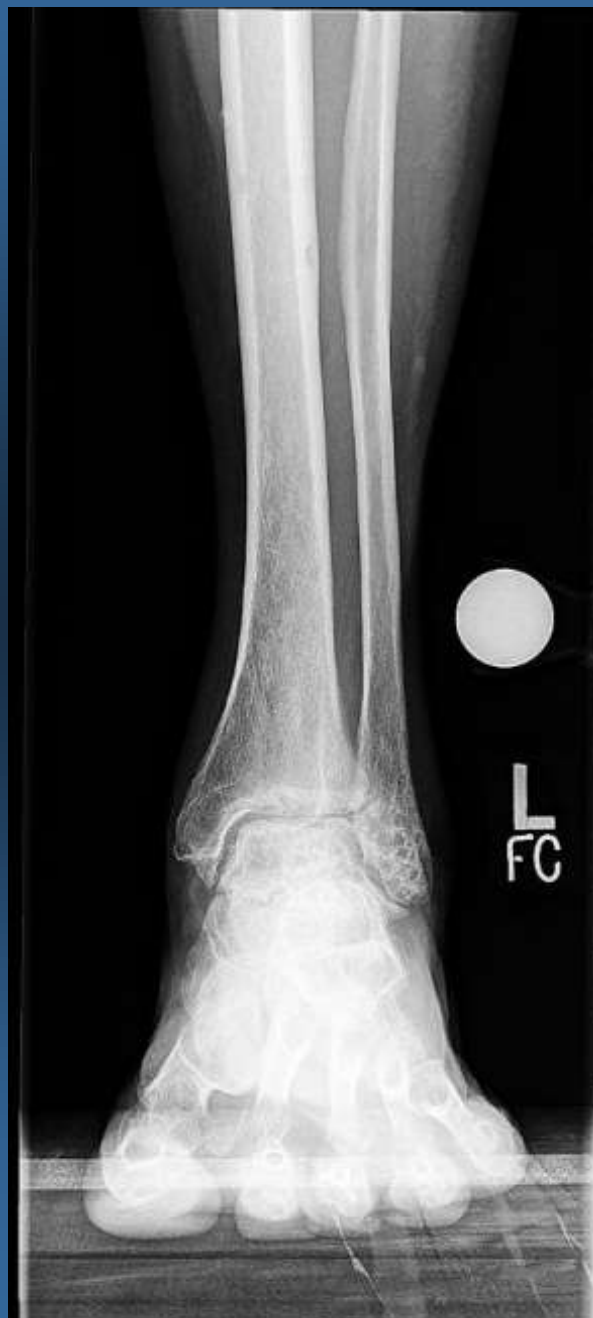Before

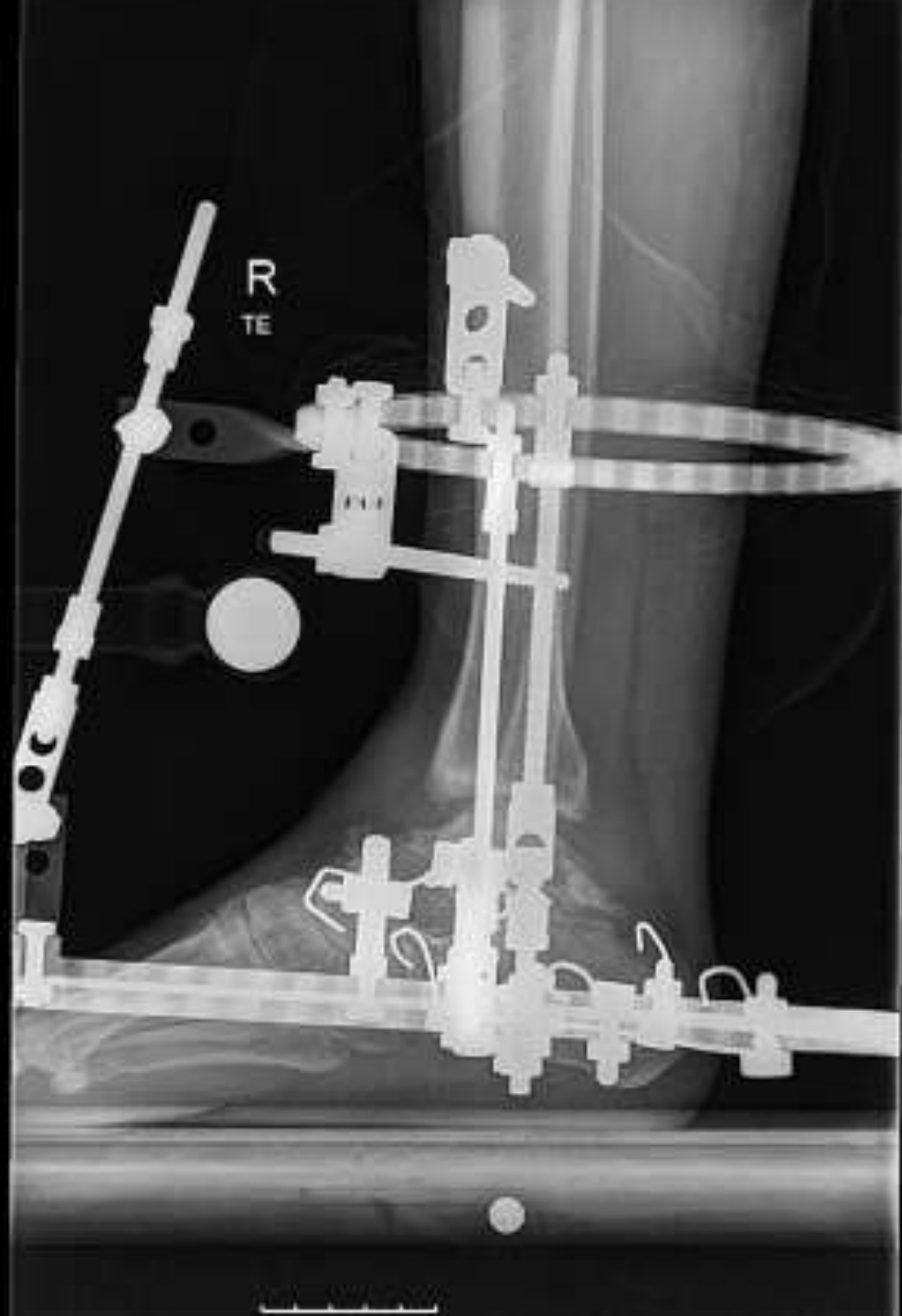


2 years



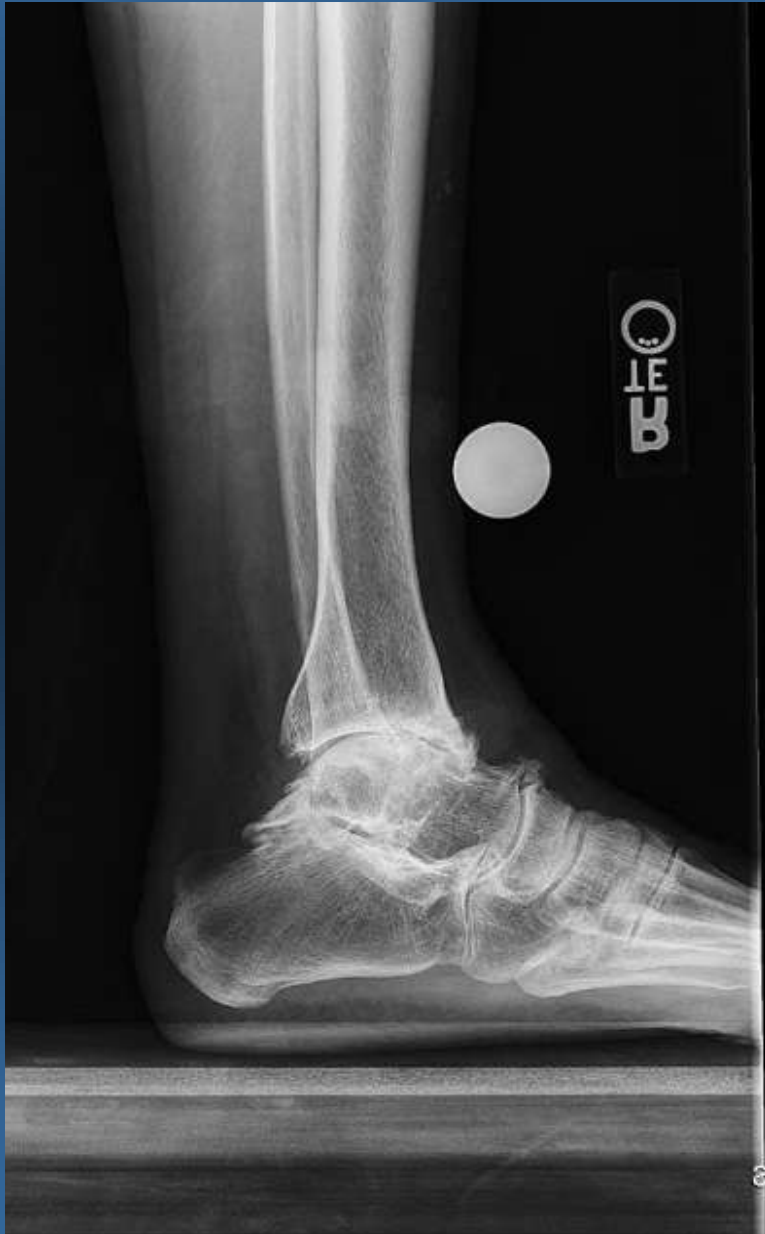




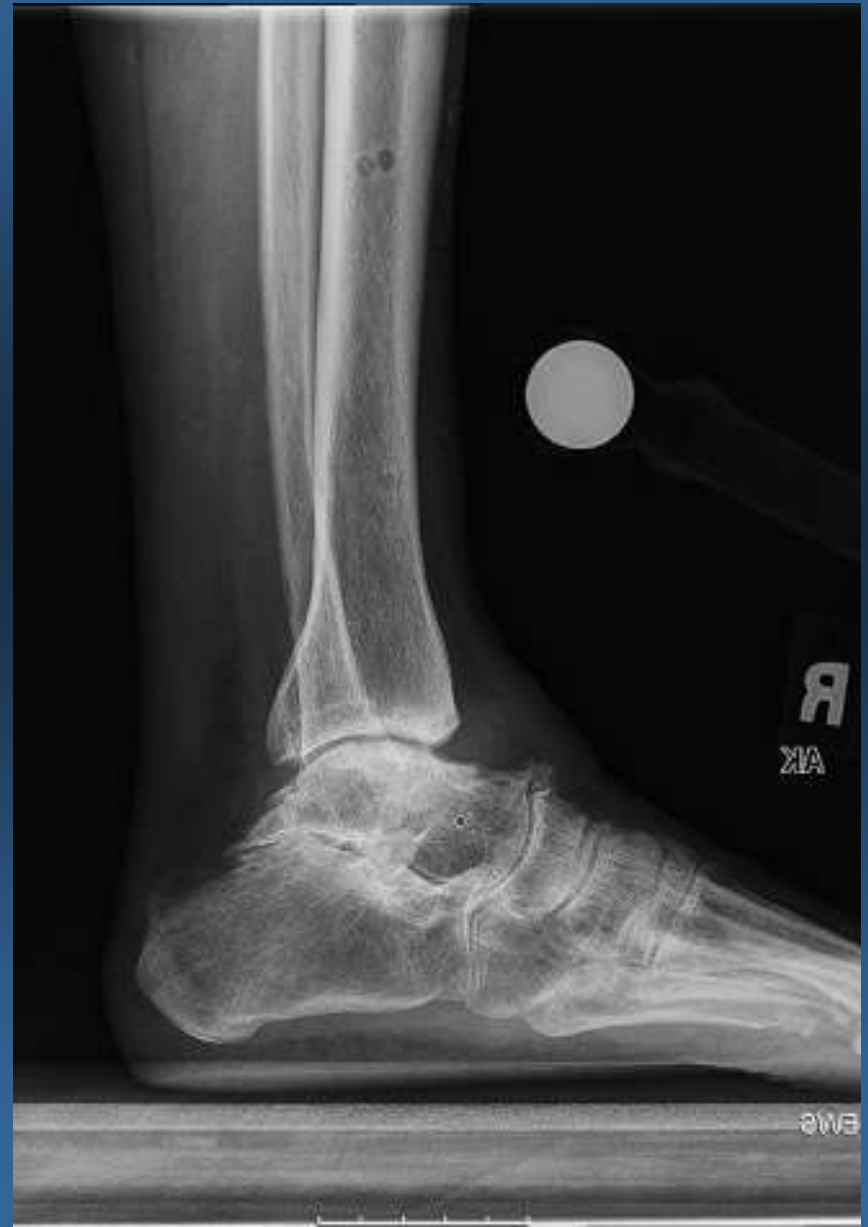


# Before

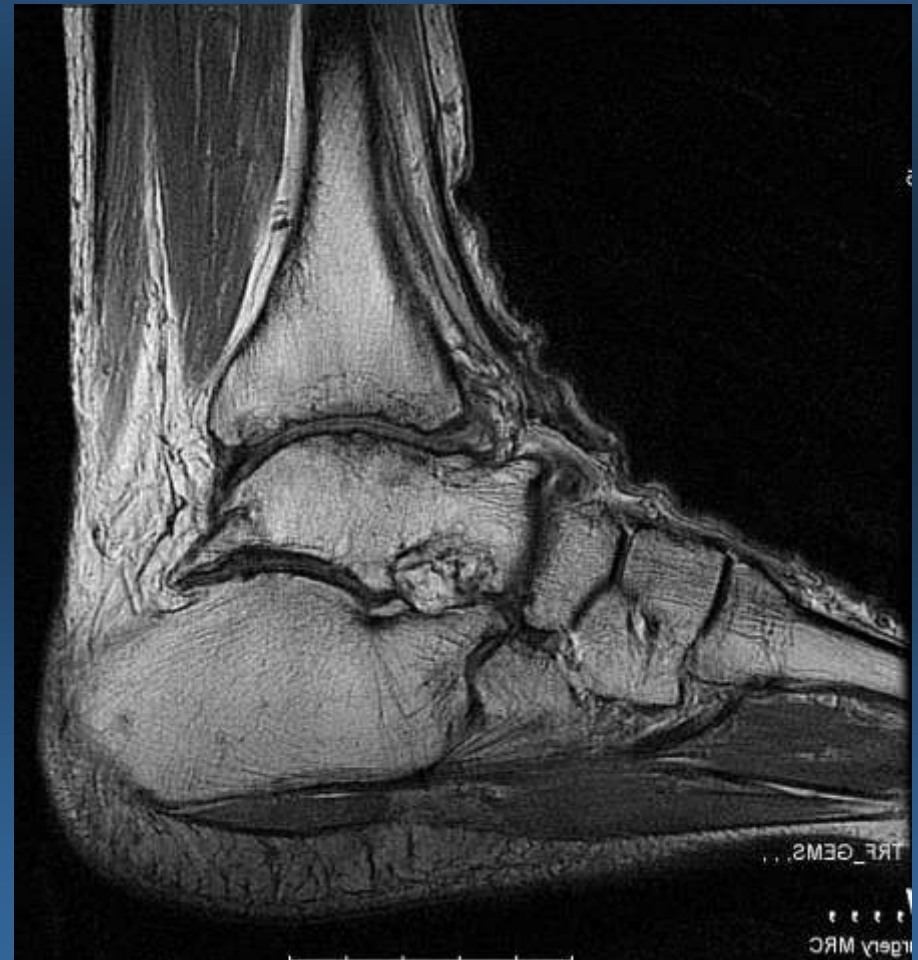
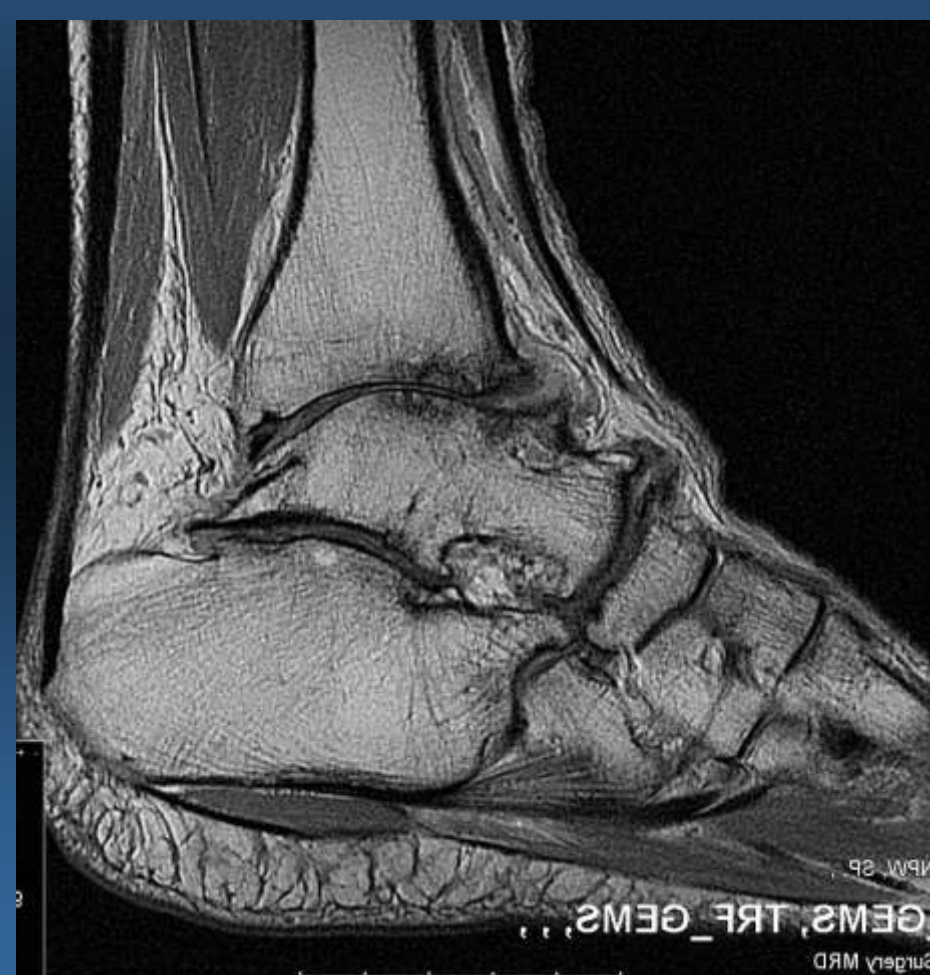
# 2 years

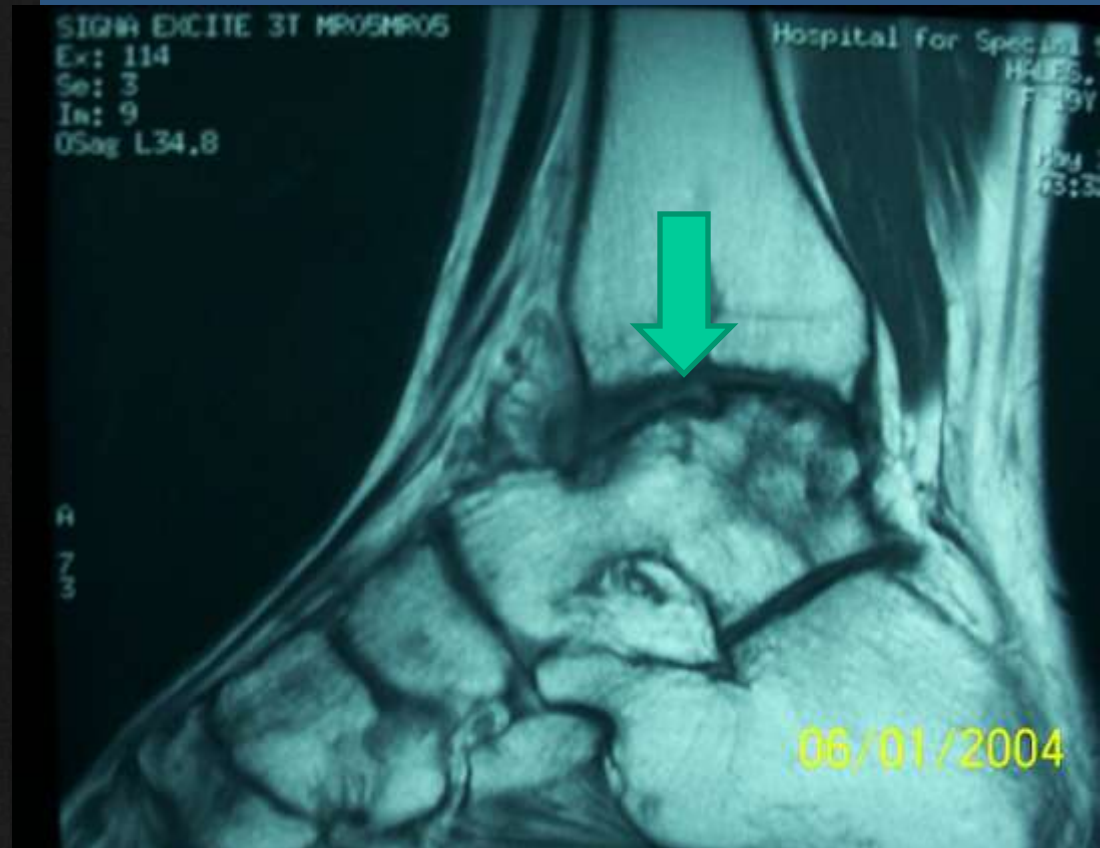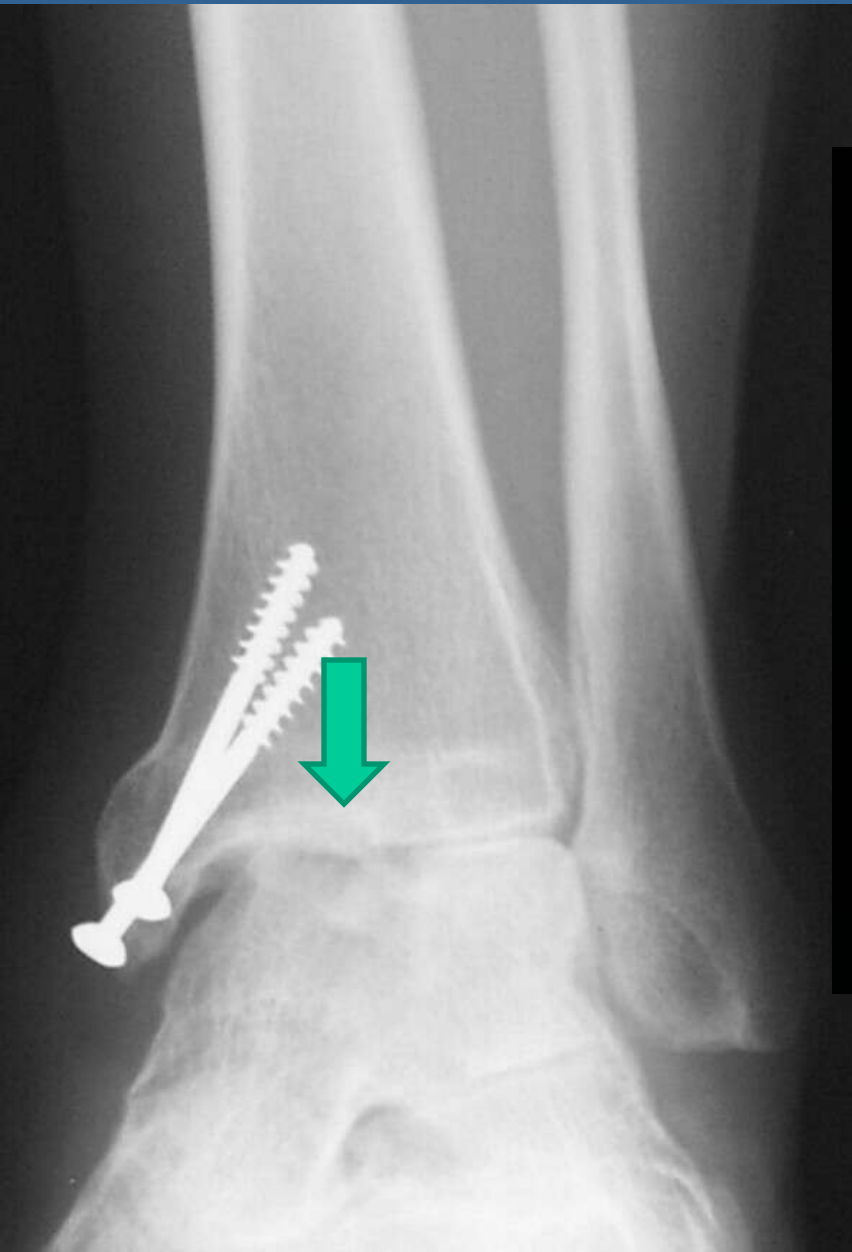


Before

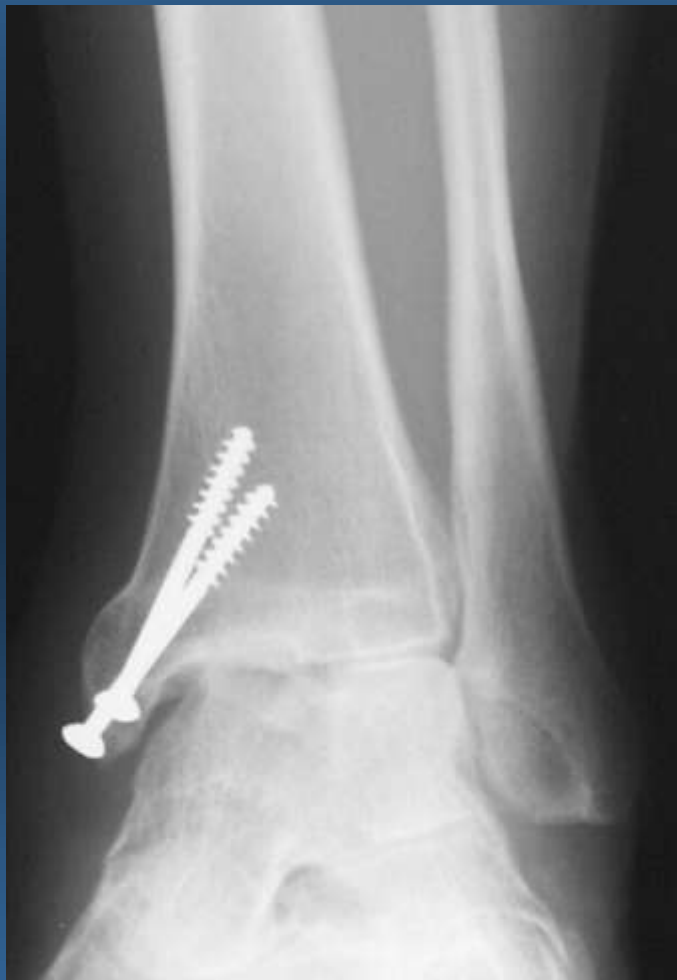2 years later



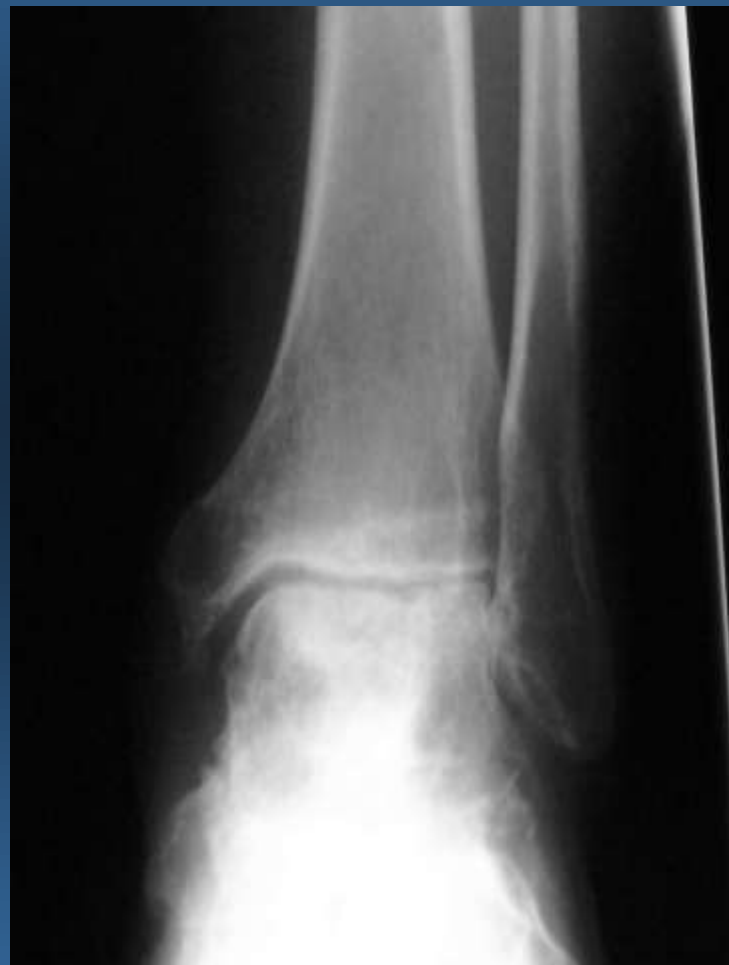# Talar osteonecrosis



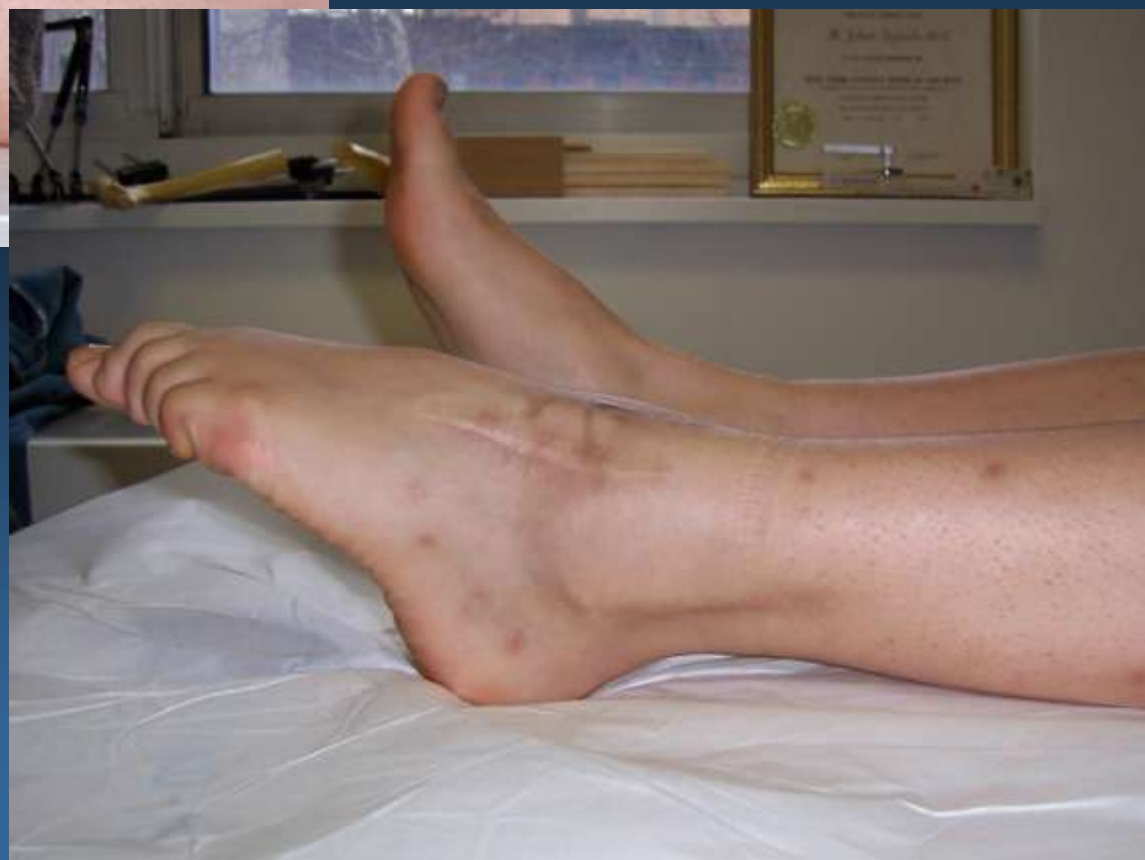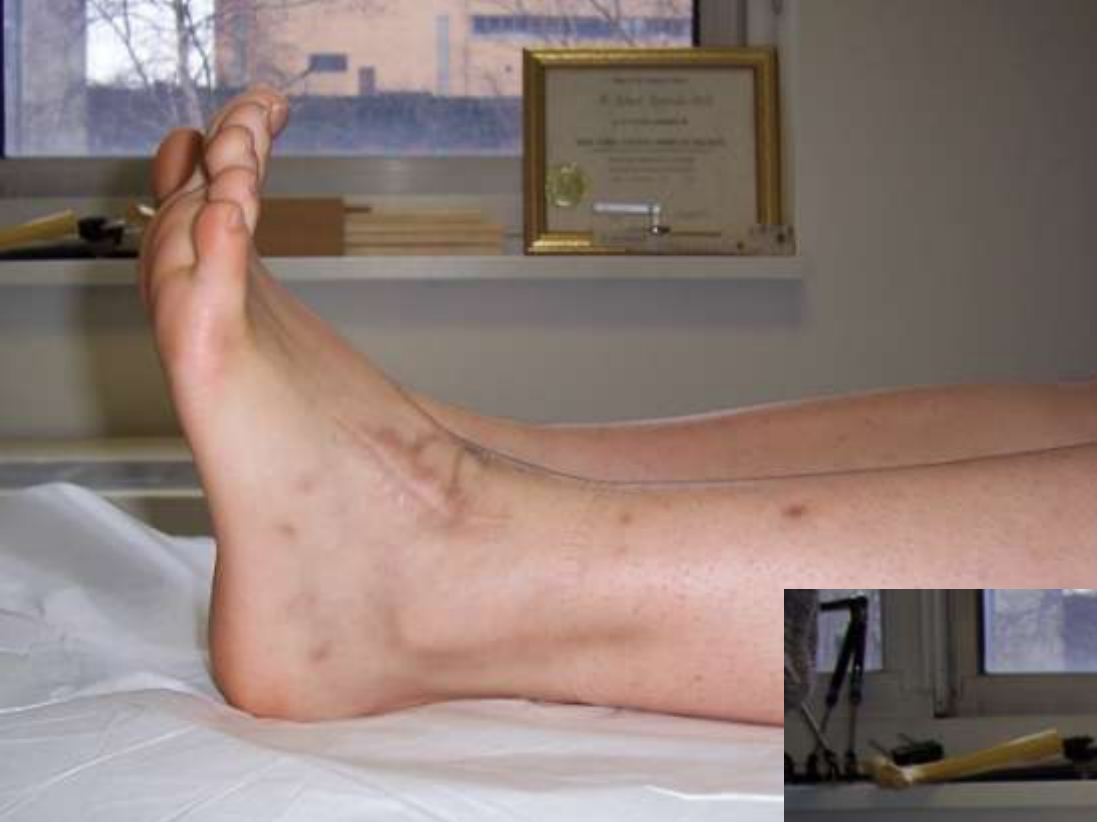Before



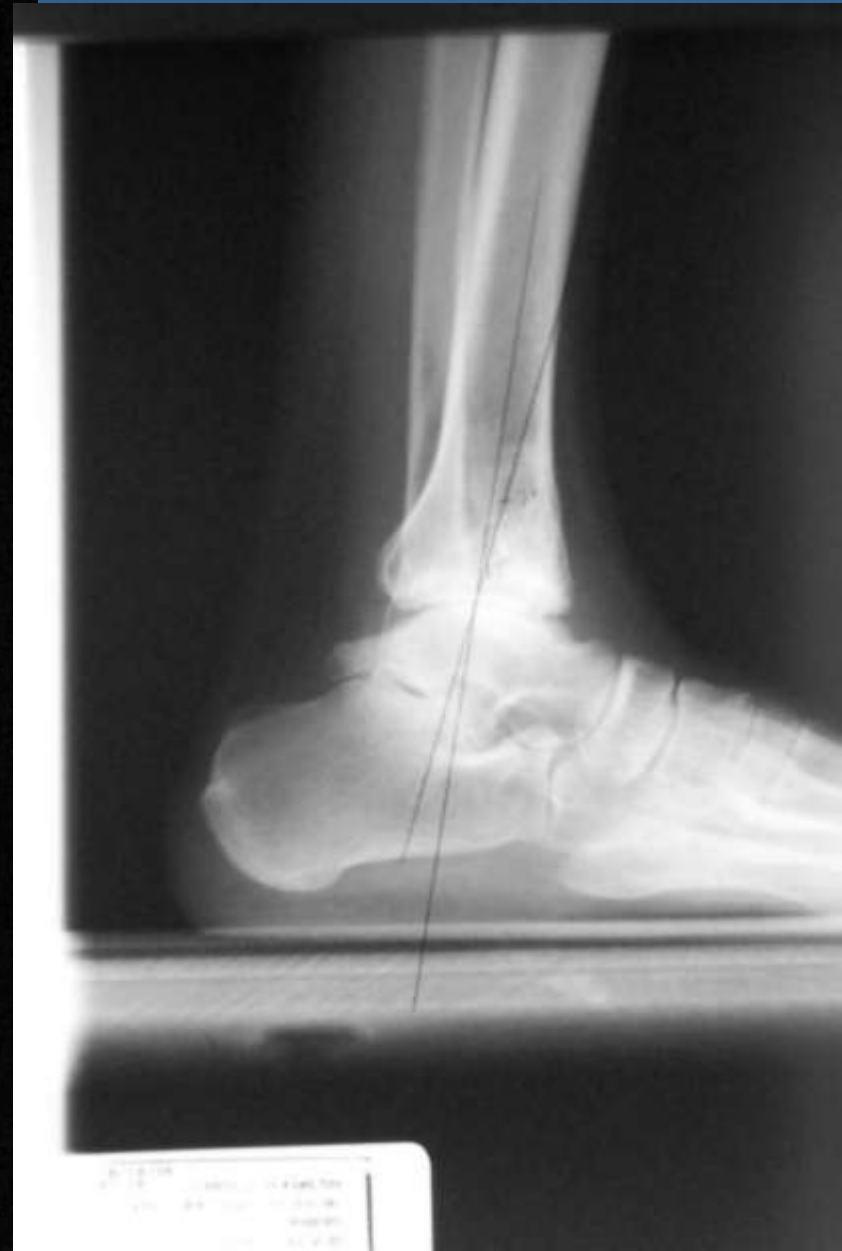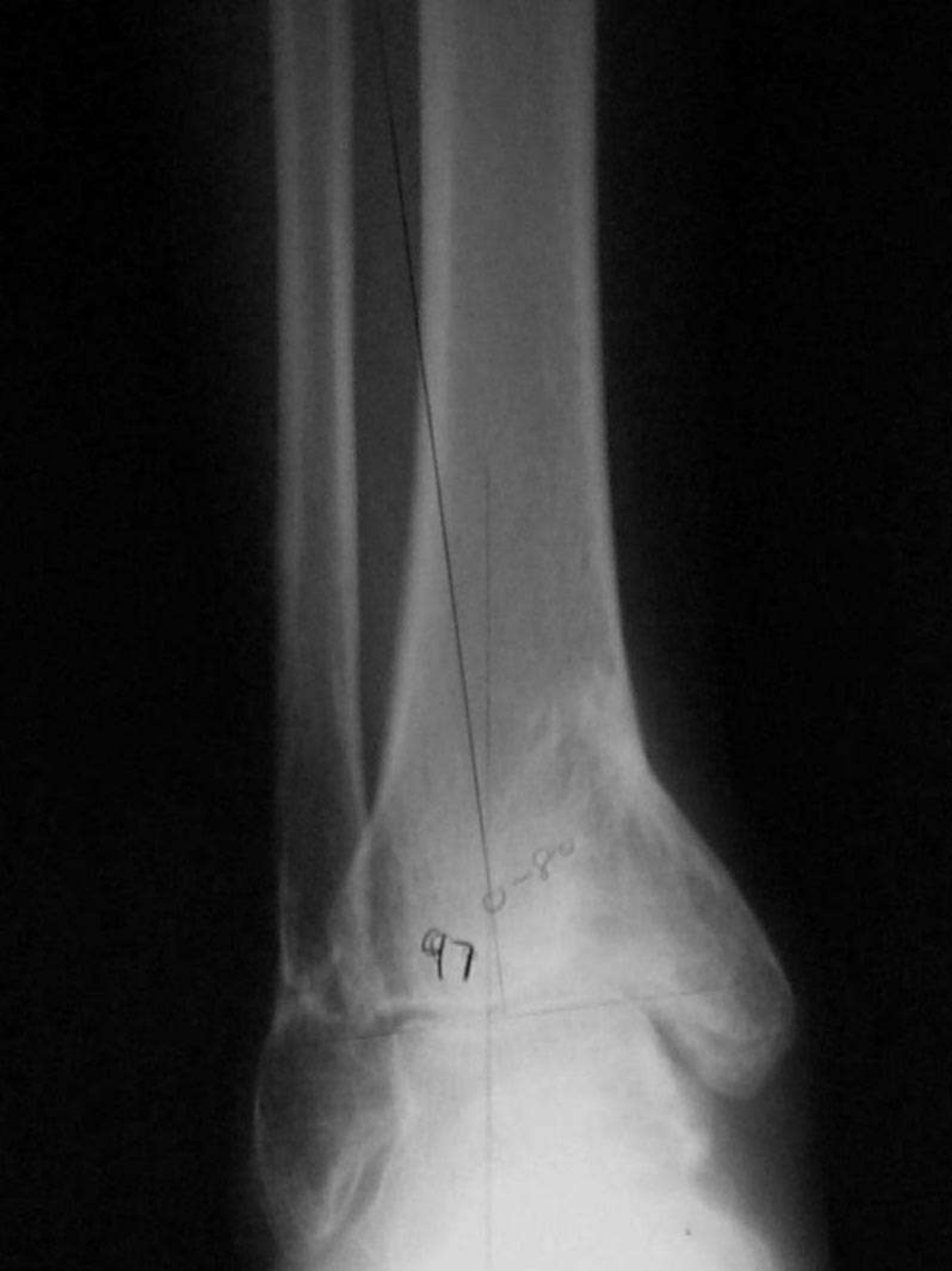2 years

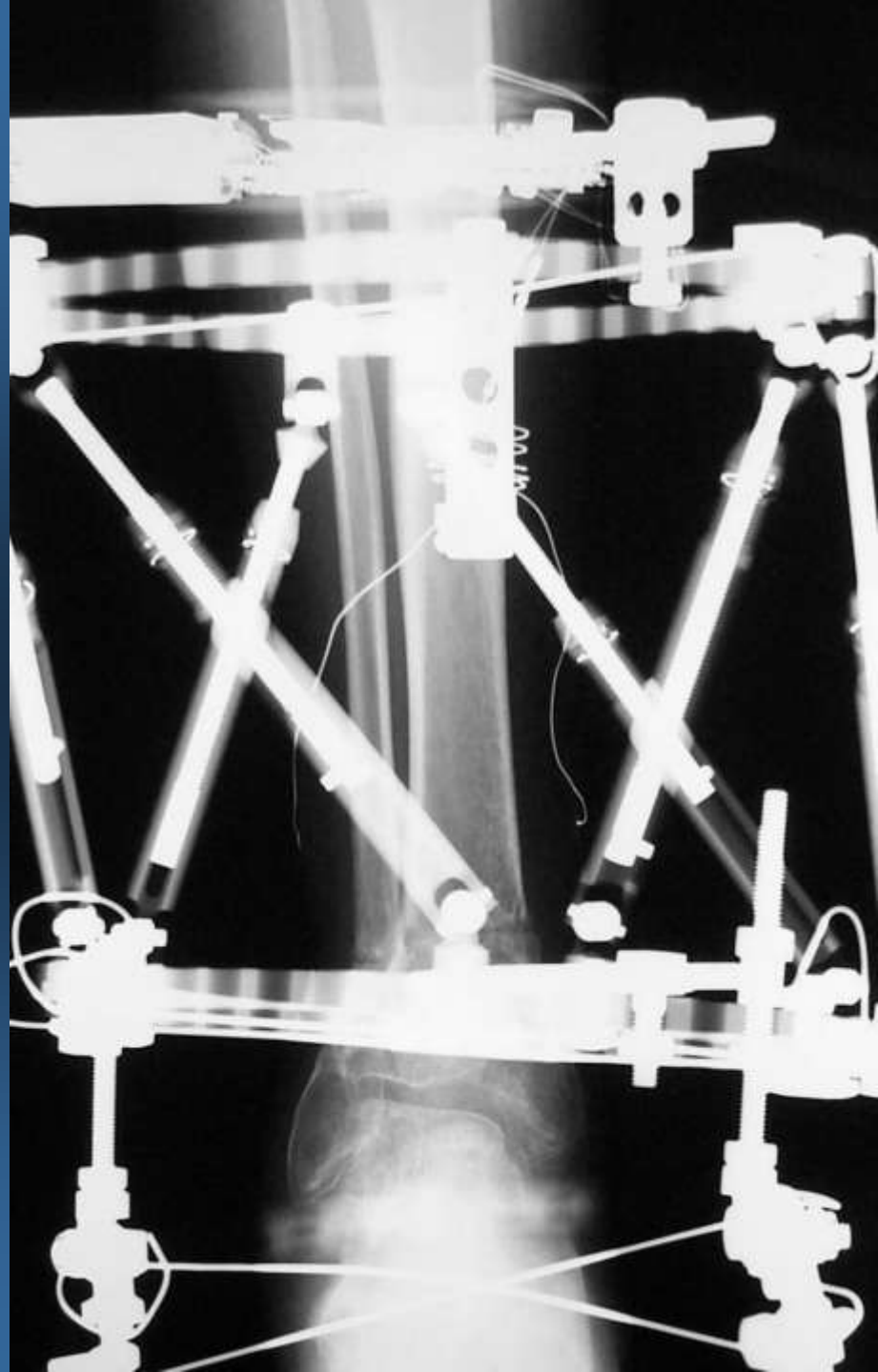
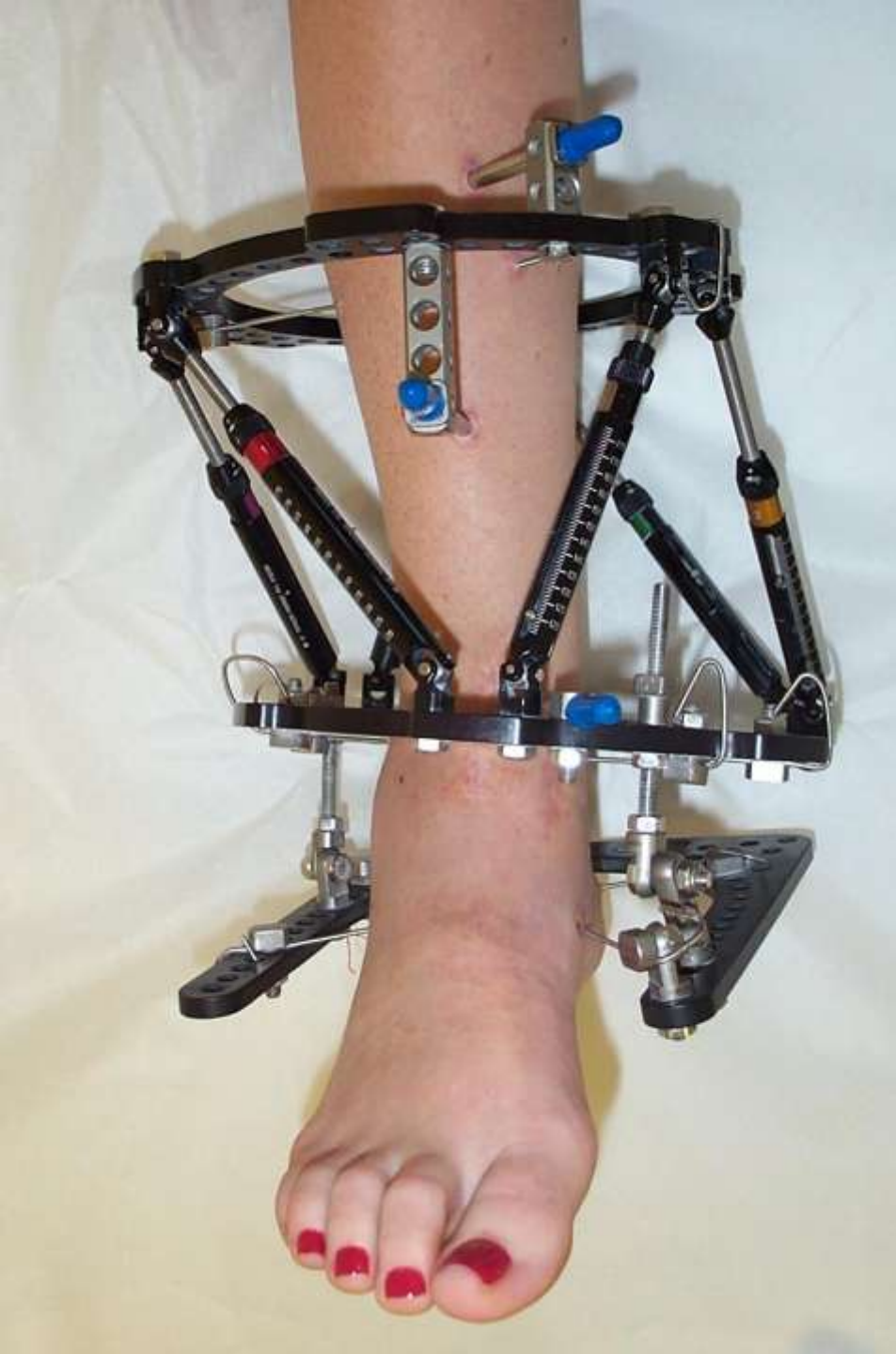








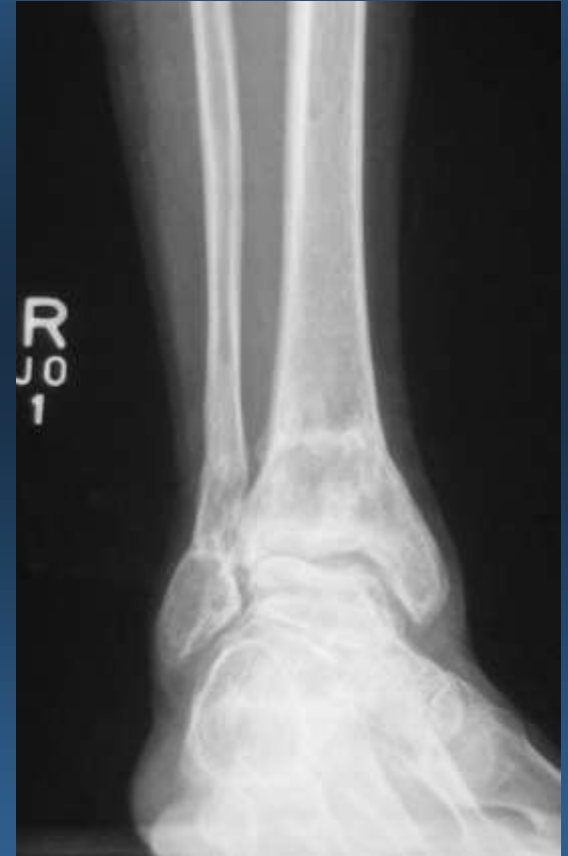
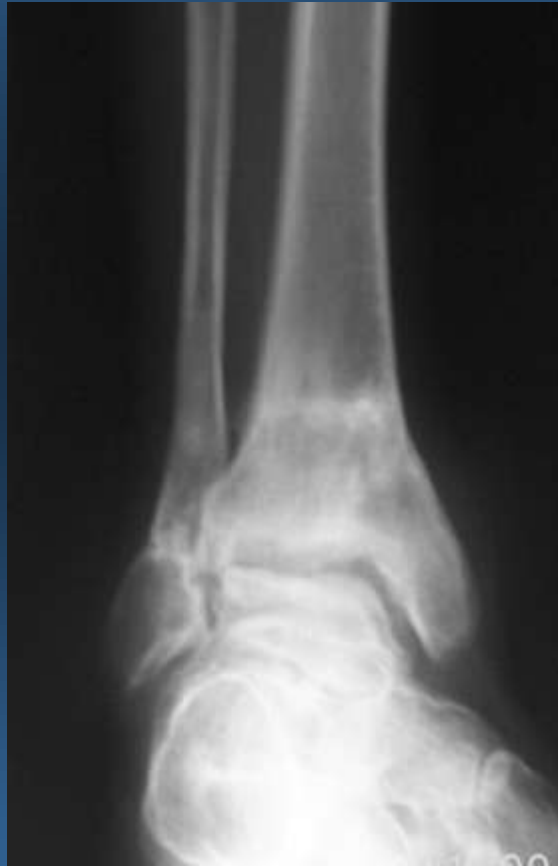
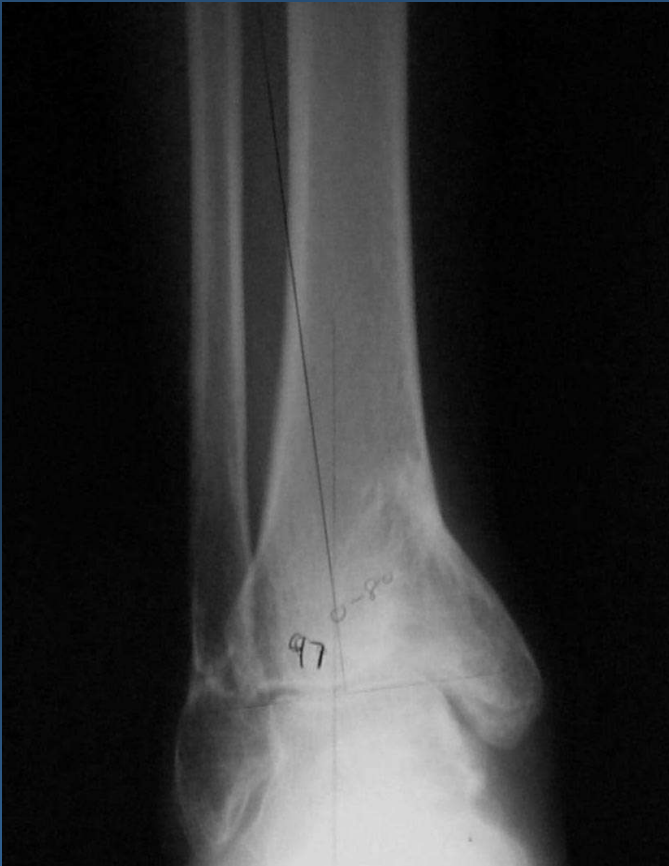

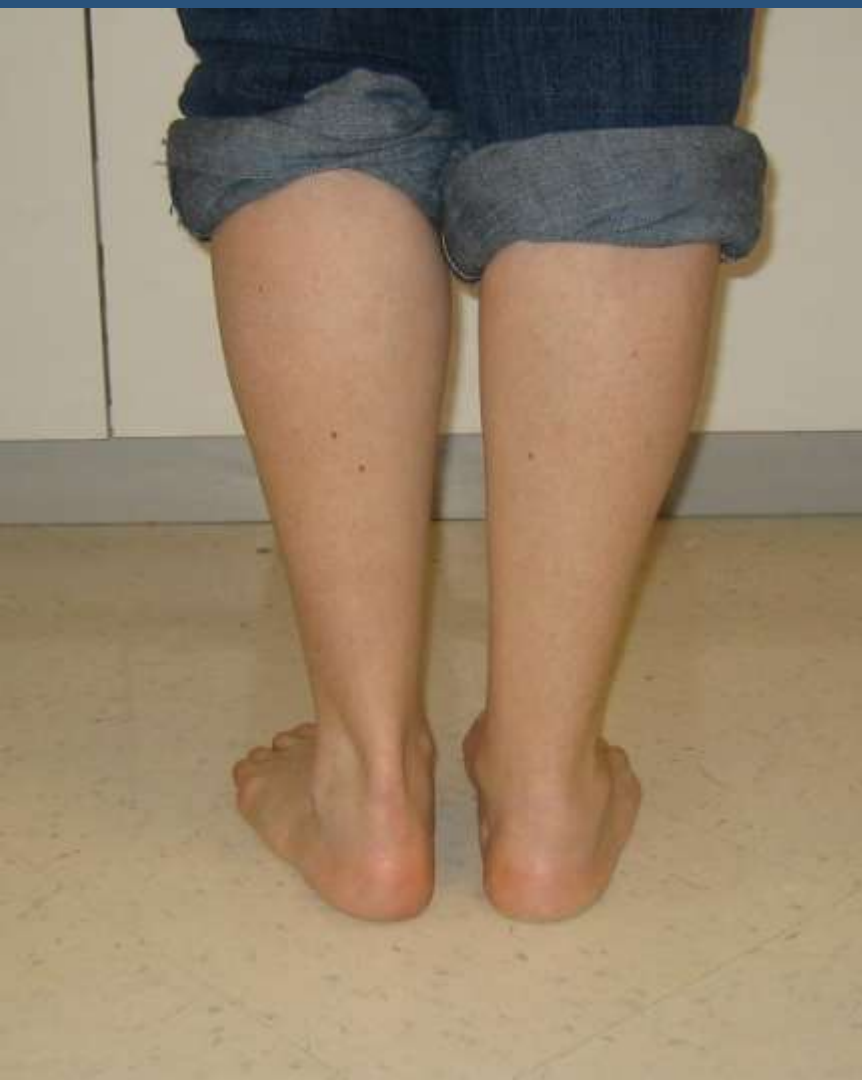Preop

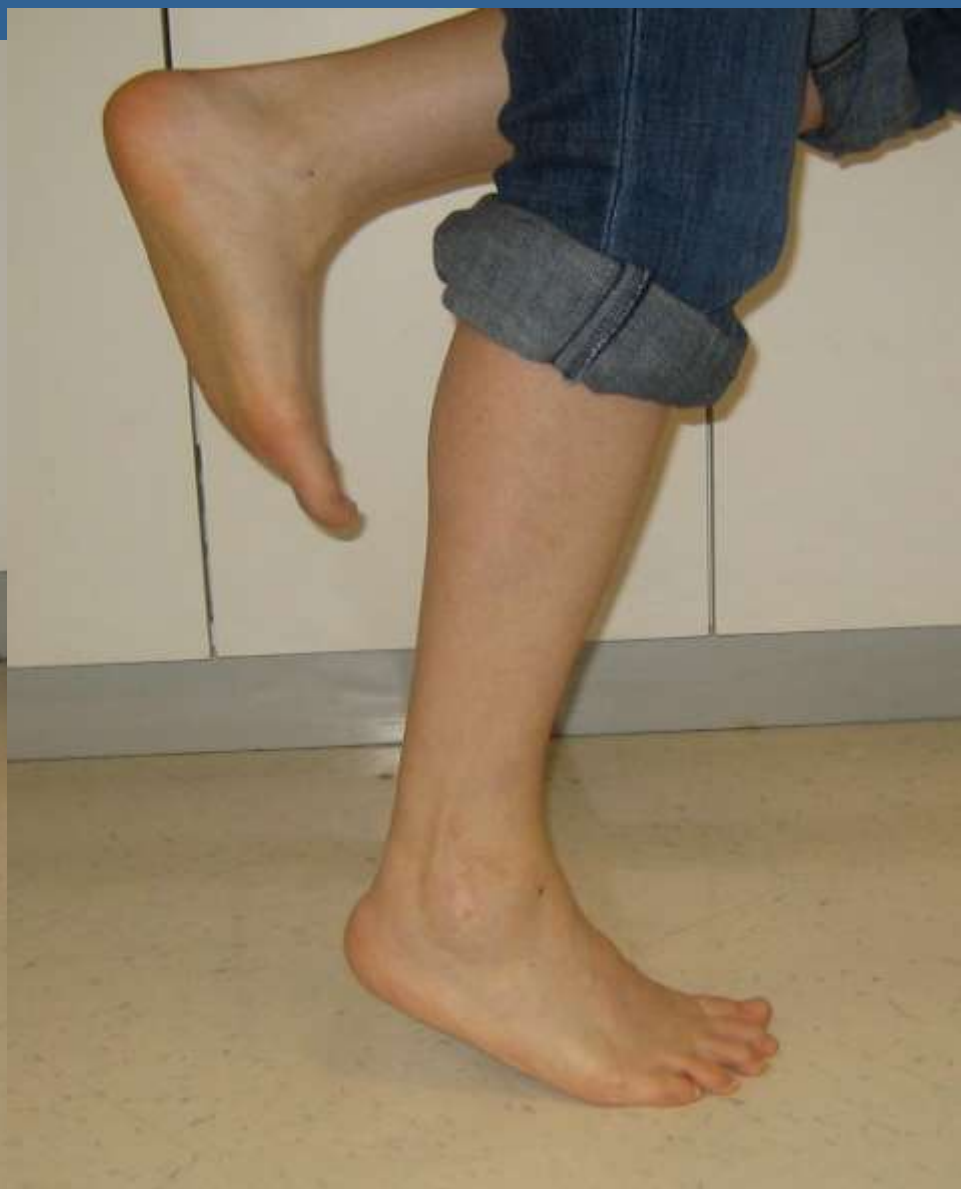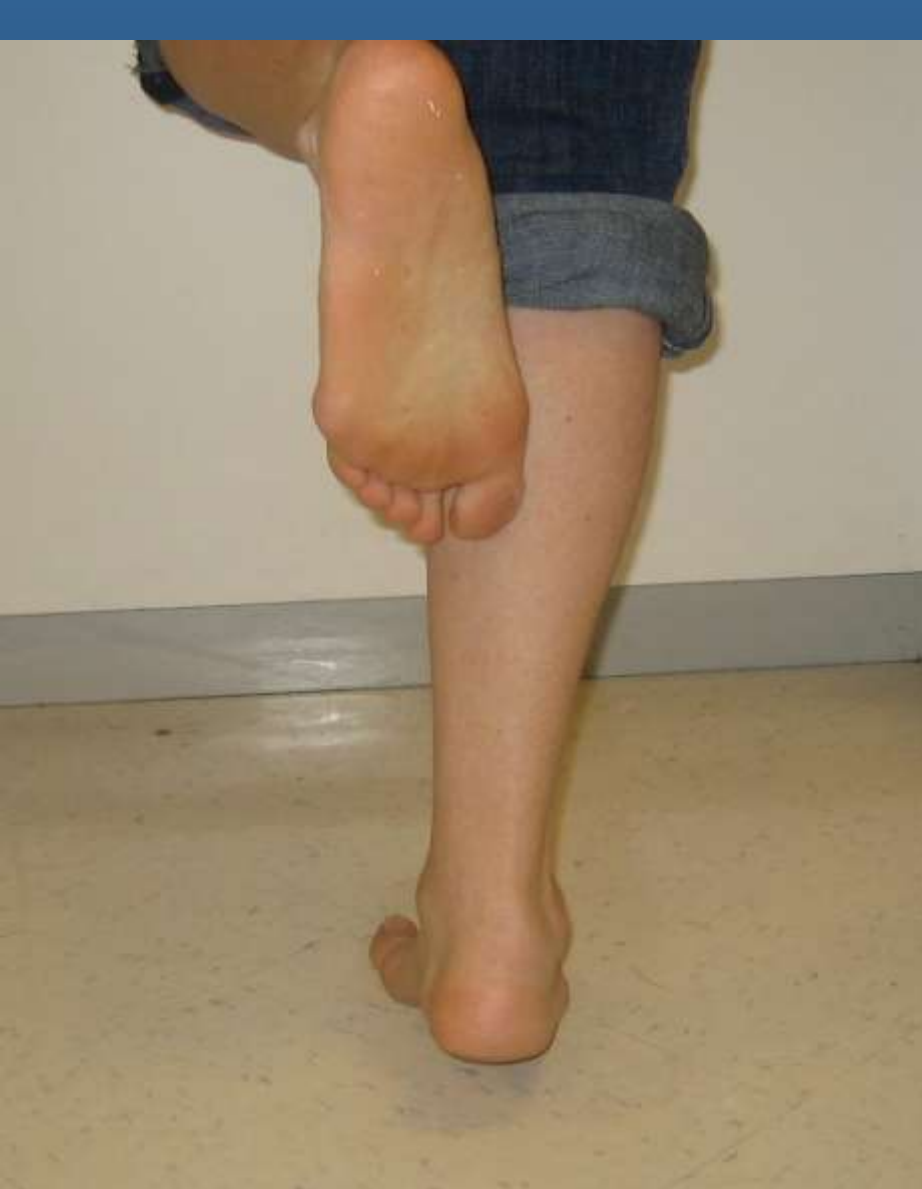2.5 years

5 years





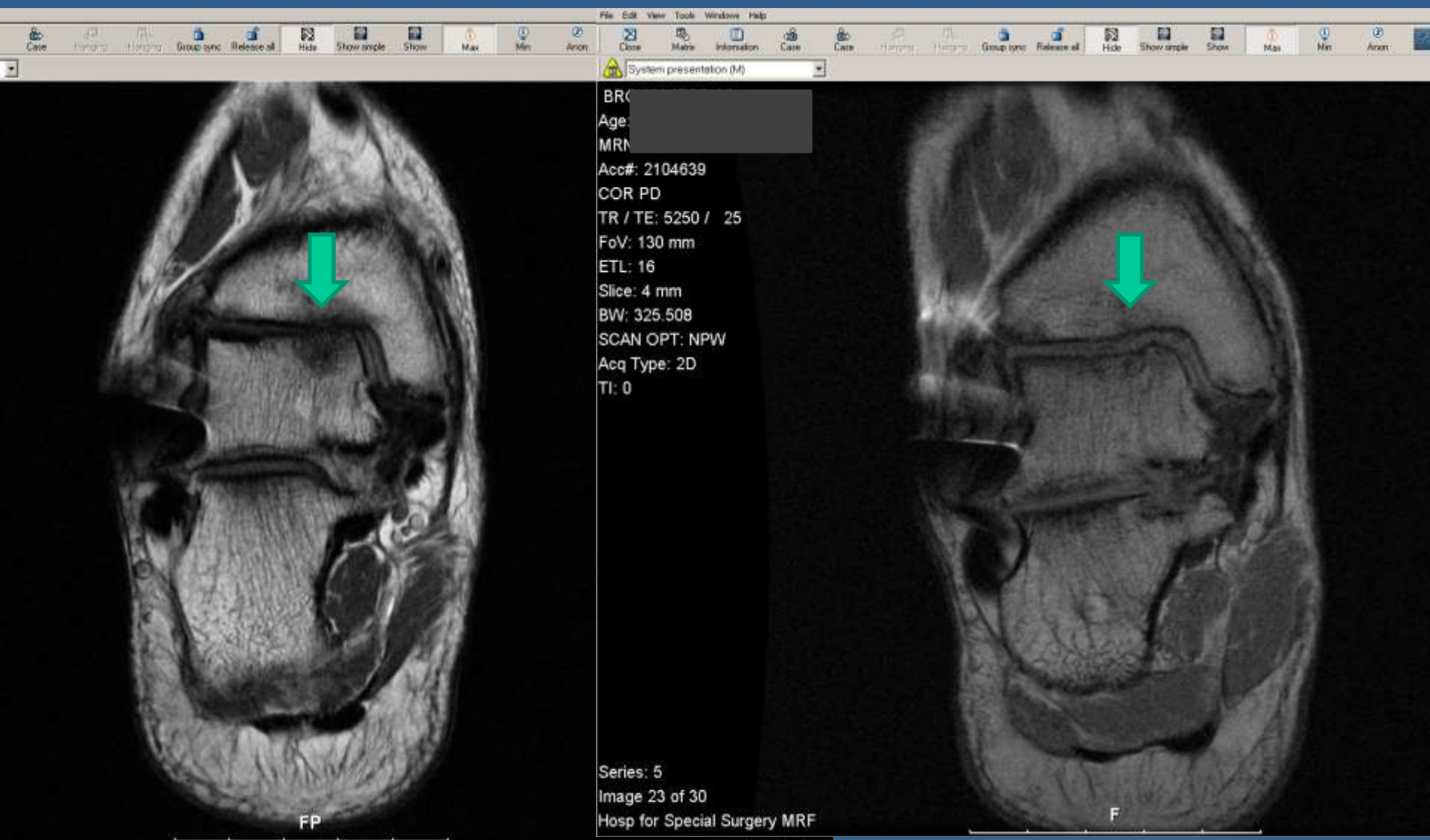




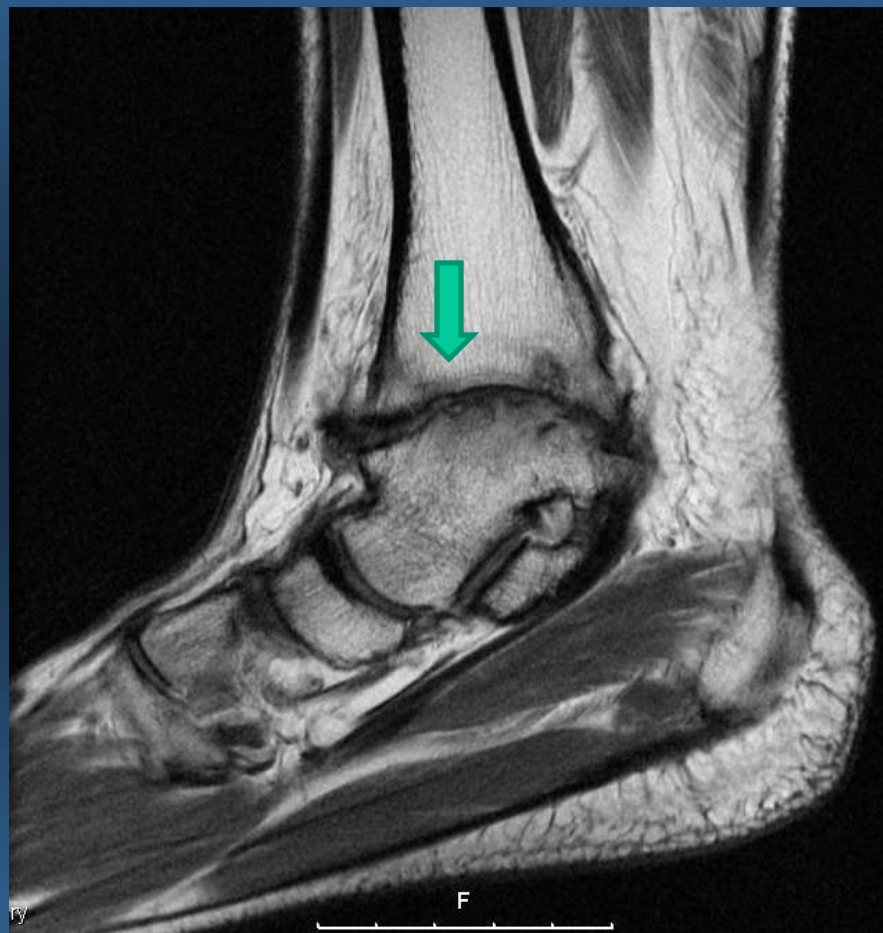

# Before

# After



# Before



# After

